

K. Singh, T. Yuzvenko

NEUROLEMOMMA OF THE ADRENAL GLAND*Ukrainian Scientific and Practical Centre for Endocrine Surgery,
Organ and Tissue Transplantation, Kyiv***INTRODUCTION**

Neurilemoma is a rare tumor of neural crest cell origin. It is usually a benign slow growing tumor, composed of Schwann cells, which normally produce the insulating myelin sheath covering the peripheral nerves. Schwann cells are very important in the regeneration of damaged peripheral nerves [1]. For reasons not yet understood, neurilemmomas are mostly benign and less than 1% become malignant, degenerating into neurofibrosarcoma. Most commonly they occur as solitary encapsulated subcutaneous tumors. More rarely, they are multiple or arise from points along the PNS, including cranial nerves, spinal roots, the brachial and lumbar-sacral plexus, or major peripheral nerves.⁽¹⁾

Most neurilemmomas occur in the head, neck, stomach [2] or limbs, with a few cases occurring in the retroperitoneal space. The cause of these neoplasms is unknown [3]. Neurilemmomas can arise from neurofibromatosis. Because these tumors can present in many locations, the clinical presentation can be varied [4]. Some may involve the spinal nerve roots and present with symptoms that mimic those of herniated disk disease of the spine [5]. Deeply situated tumors predominate in the posterior mediastinum and the retroperitoneum. Visceral neurilemmomas, especially of the adrenal gland, are extremely rare and are usually discovered incidentally. Adrenal neurilemmomas are thought to arise from Schwann cells associated with the phrenic nerve, the vagus nerve, and the sympathetic trunk that innervate the adrenal medulla [6].

CASE REPORT

In march 2006, a 41 year old male patient was referred to the Ukrainian scientific and practical centre for endocrine surgery and organ transplantation as a case of a retroperitoneal tumor (incidentaloma) for further diagnostic evaluation and treatment. Physical examination then revealed a healthy looking man 177 cm tall and 105 kg in weight, body mass index 33.5, with first stage obesity. No abnormalities were found. Thyroid sonography was normal. Abdominal sonography revealed an hyperechoic round mass (52 mm) in the upper pole of the left kidney.

Laboratory data revealed normal hematology and biochemistry. Endocrine studies showed normal levels of: urine 17-oxycorticosteroid – 3.9 mcmol/day, 17-corticosteroid – 17.6 mcmol/day, 11 oxycorticosteroid – 0.16 mcmol/day. Catecholamine's: adrenaline – 6.57 nmol/day, noradrenalin – 14.4 nmol/day, dopamine – 176.4 nmol/day, VMA – 4.95 mcmol/day.

Computed tomography (CT) revealed a well-marginated heterogeneously enhanced capsulated mass 60x50mm in the left adrenal region.

The patient underwent laparoscopic left adrenalectomy. Pathologic finding of the left adrenal gland showed a picture of a benign neurilemoma and hyperplasia of the adrenal cortex. The post operative course was smooth and the patient was discharged after 2 weeks of hospital stay. During the follow up period till 2014 endocrine studies and abdominal CT revealed no evidence of tumor recurrence. In 2009 thyroid sonography revealed non toxic multinodular goiter and blood tests revealed hypothyroidism. The patient was prescribed thyroxine 100 mcg 1 tablet daily. Routine monitoring of TSH was recommended.

In 2014 the patient underwent a routine check up at our hospital. Abdominal CT revealed microadenoma (13 mm, density -4 HU to +7 HU non contrast image) of the right adrenal gland and adrenal hyperplasia, Intra venous contrast imaging revealed during the venous phase (60 sec) density of +67 HU to +79 HU, wash out phase (15 min.) -2 HU to +11 HU.

Laboratory data revealed normal hematology and biochemistry. Endocrine studies showed normal levels of: Urine metanephrines – 346.9 mcg/day, cortisol (overnight dexamethasone test) – 0.6 mcg/dl, aldosterone – 17.3 ng/l, rennin 4.83 ng/l, TSH – 6.21 μ U/mL, ARR – 3.58, plasma potassium – 4.6 mmol/l.

The patient was recommended to have a routine checkup (abdominal CT and blood tests) after 1 year as the laboratory findings were in the normal range and the patient was normotensive without any complaints. The dose of thyroxine was corrected to 125 mcg/daily.

DISCUSSION

Neurilemoma is a benign, slow-growing, encap-

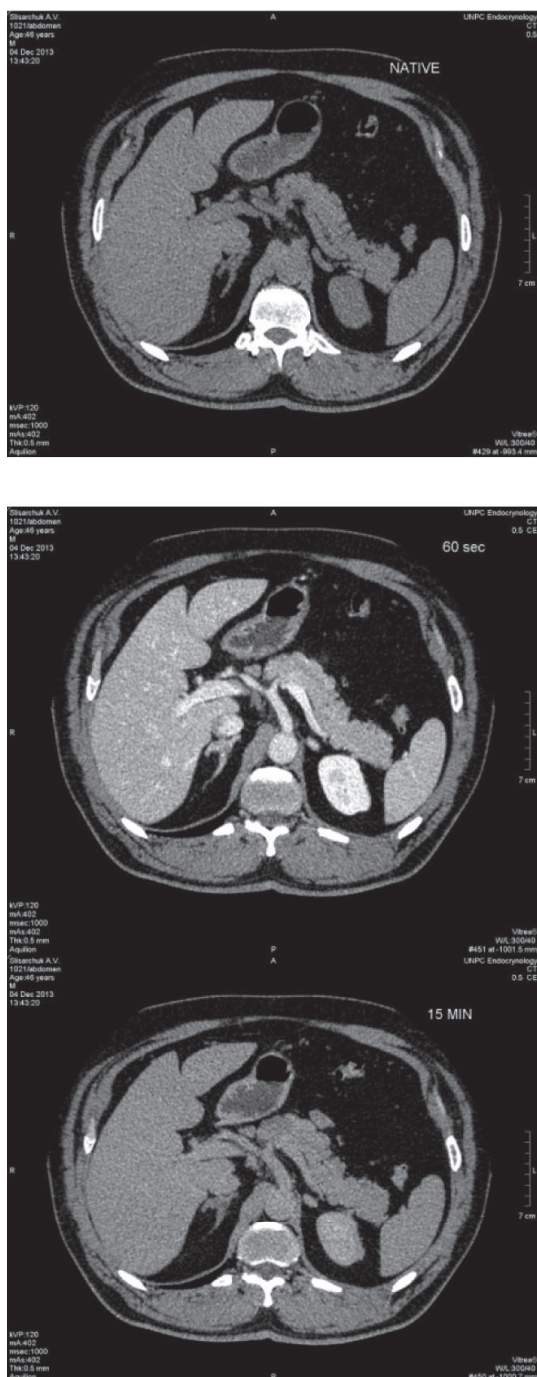


Fig. 1, 2, 3. Computed tomography (CT) of the adrenal gland:
 1 – non contrast phase density 1-4 HU to + 7 HU,
 2 – venous phase (60 sec) density of 67 HU to 79 HU,
 3 – wash out phase (15 min.) -2 HU to +11 HU.

sulated neoplasm in which the principal component arises from neural crest cells and comprises differentiated Schwann cells in a poorly collagenized stroma. Neurilemmomas were first described by Verocay in 1908, with further sub-classification into two distinct histologic patterns performed by Antonini in 1920 [7]. On computed tomography, a neurilemmoma

appears as a well-demarcated, round or oval mass that may be homogeneous. However, other cases in the literature have shown prominent cystic degeneration and calcifications [8].

A 2002 National Institutes of Health (NIH), science statement, on the management of adrenal incidentalomas concludes that lesions greater than 6 cm should be excised, those less than 4 cm with imaging characteristics that appear benign should generally not be resected, and those between 4 cm and 6 cm can be either closely observed or resected. However, non-secreting tumors with of size >4 cm can be excised with an added benefit of definitive diagnosis [9].

The differential diagnosis of adrenal incidentaloma can be extensive and ranges from cortical lesions such as adenoma and carcinoma to medullary lesions such as neuroblastoma, ganglioneuroma, pheochromocytoma, neurilemmoma and neurofibroma. Rare lesions like leiomyosarcoma and malignant peripheral nerve sheath tumors can also occur.

Histologically, the growth patterns in neurilemmomas include Antoni type A neurilemmoma and type B neurilemmoma [1]. Immunohistochemistry of adrenal neurilemmoma shows strong and diffuse staining for S-100. They also display pericellular reactivity for collagen IV, laminin, and show absence of reactivity for keratin, desmin, actin, muscle-related antigens, HMB-45, Melan-A, chromogranin, synaptophysin, and CD34 [10].

The management of neurilemmoma requires complete surgical excision. Laparoscopic adrenalectomy is safe and feasible for diagnosis and treatment of benign adrenal neurolemoma [11].

In conclusion, total excision of benign neurolemoma is associated with favorable outcome in patients, but as our case depicts regular follow up is needed, as our patient presented with a hormonally inactive micro adenoma and adrenal hyperplasia of the right adrenal gland 8 years post left adrenalectomy.

REFERENCES

1. MacCollin M, Woodfin W, Kronn D, Short MP. Schwannomatosis: a clinical and pathologic study // *Neurology*. – 1996; 46: 1072-9.
2. Lin CS, Hsu HS, Tsai CH, Li WY, Huang MH. Gastric schwannoma. *J Chin Med Assoc.* – 2004; 67: 583-6.
3. Roche PH, Bouvier C, Chinot O, Figarella-Branger D. Genesis and biology of vestibular schwannomas // *Prog Neurol Surg.* – 2008; 21: 24-31.
4. Guerrissi JO. Solitary benign schwannomas in major nerve systems of the head and neck // *J Craniofac Surg.* – 2009; 20 (3): 957-61.
5. Bakar B, Sumer MM, Cila A, Tekkok IH. An extreme lateral

- lumbar disc herniation mimicking L4 schwannoma. *Acta Neurol Belg.* – 2009; 109 (2): 155-8.
6. *Lau SK, Spagnolo DV, Weiss LM.* Schwannoma of the adrenal gland: report of two cases // *Am J Surg Pathol.* – 2006; 30 (5): 630-634.
 7. *Woodruff JM KH, Louis DN, Scheithauer BW.* Schwannoma. Lyon, France: IARC Press, 2000.
 8. *Korets R, Berkenblit R, Ghavamian R.* Incidentally discovered adrenal schwannoma // *JSLs.* – 2007; 11 (1): 113-115.
 9. *Tarcoveanu E, Dimofte G, Bradea C, et al.* Adrenal schwannoma // *JSLs.* – 2009; 13 (1): 116-119.
 10. *Chwen-Yi Yang, Chien-Wen Chou, Ming-Bin Lin et al.* Schwannomas of the Left Adrenal Gland and Posterior Mediastinum // *J Chin Med Assoc.* – 2009; 72: 83-86.
 11. *Morrison KB, McAuley IW, Kinahan JF.* Laparoscopic resection of a juxta-adrenal schwannoma // *Canadian J Urol.* – 2004; 11: 2309-11.

РЕЗЮМЕ

Неврилемома (невринома, шваннома) надниркової залози**К. Сінх, Т. Юзвенко**

Доброякісна пухлина, зв'язана зі шванівською оболонкою нервів. Виникає у м'яких тканинах за ходом нервових стовбурів, а також черепних нервів, рідше – у внутрішніх органах. Буває поодинокую у вигляді вузла невеликих розмірів (2-3 см), зв'язаного з нервовим стовбуром. Дуже зрідка пухлина досягає великих розмірів, причому вага її може бути 2,5 кг і більше. Описано клінічний випадок: 2006 року було прооперовано чоловіка, 1965 р. н., із приводу утворення заочеревинного простору розмірами 60×50 мм, гормонально неактивного. Патогістологічний висновок: неврилемома лівої надниркової залози, гіперплазія коркового шару надниркової залози. На плановому обстеженні 2014 року за результатами МСКТ виявлено мікро аденому та гіперплазію правої надниркової залози.

Ключові слова: неврилемома, надниркові залози, лікування.

РЕЗЮМЕ

Неврилемома (невринома, шваннома) надпочечника**К. Сінх, Т. Юзвенко**

Доброкачественная опухоль, связанная со шванновской оболочкой нервов. Образуется в мягких тканях по ходу нервных стволов, а также черепных нервов, реже – во внутренних органах. Бывает одиночной и представляет собой узел небольших размеров (2-3 см), связанный с нервным стволом. В редких случаях опухоль имеет большие размеры, масса ее может достигать 2,5 кг и более. Описан клинический случай: в 2006 году мужчина 1965 г. р. был оперирован по поводу образования забрюшинного пространства размерами 60×50 мм, гормонально неактивного. Патогистологическое заключение: неврилемома левого надпочечника, гиперплазия коркового слоя надпочечника. В 2014 году на плановом осмотре на МСКТ выявлена микроаденома и гиперплазия правого надпочечника.

Ключевые слова: неврилемома, надпочечники, лечение.

SUMMARY

Neurilemoma (Schwannoma) of the adrenal gland**K. Singh, T. Yuzvenko**

It's a benign tumor composed of Schwann cells. It occurs as a solitary encapsulated subcutaneous tumor of spinal roots, cranial nerves, rarely extending to the internal organs. It generally presents itself as a small tumor (2-3 cm in diameter), in rare cases the tumor can weigh up to 2.5 kg. Case report is about a male patient (YOB 1965) who was diagnosed in 2006 with a hormonally inactive retroperitoneal tumor (60×50 mm). Pathologic finding of the left adrenal gland showed a picture of a benign neurilemoma and hyperplasia of the adrenal cortex. In 2014 during routine checkup abdominal CT revealed microadenoma and hyperplasia of right adrenal gland.

Key words: Neurilemoma, adrenal gland, treatment.

Дата надходження до редакції 13.01.2015 р.